

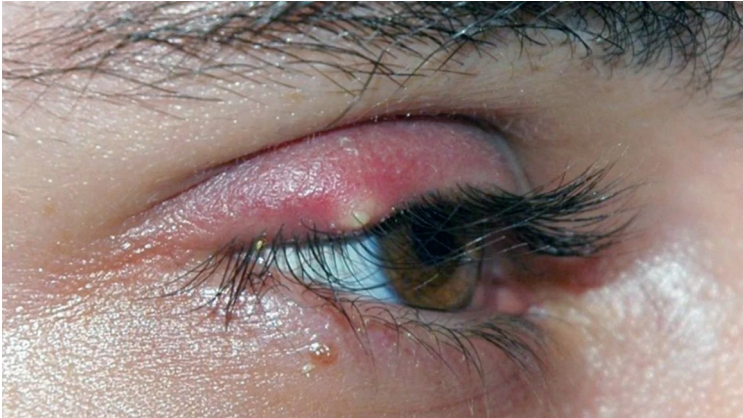Hordeolum & Chalazion

Hordeolum (Stye)

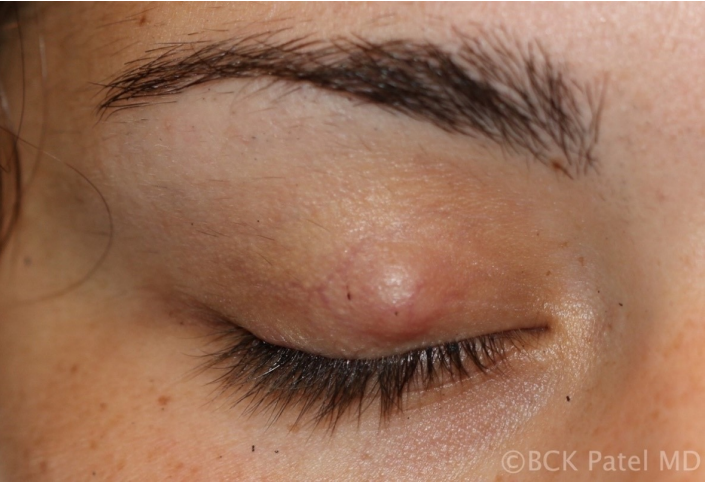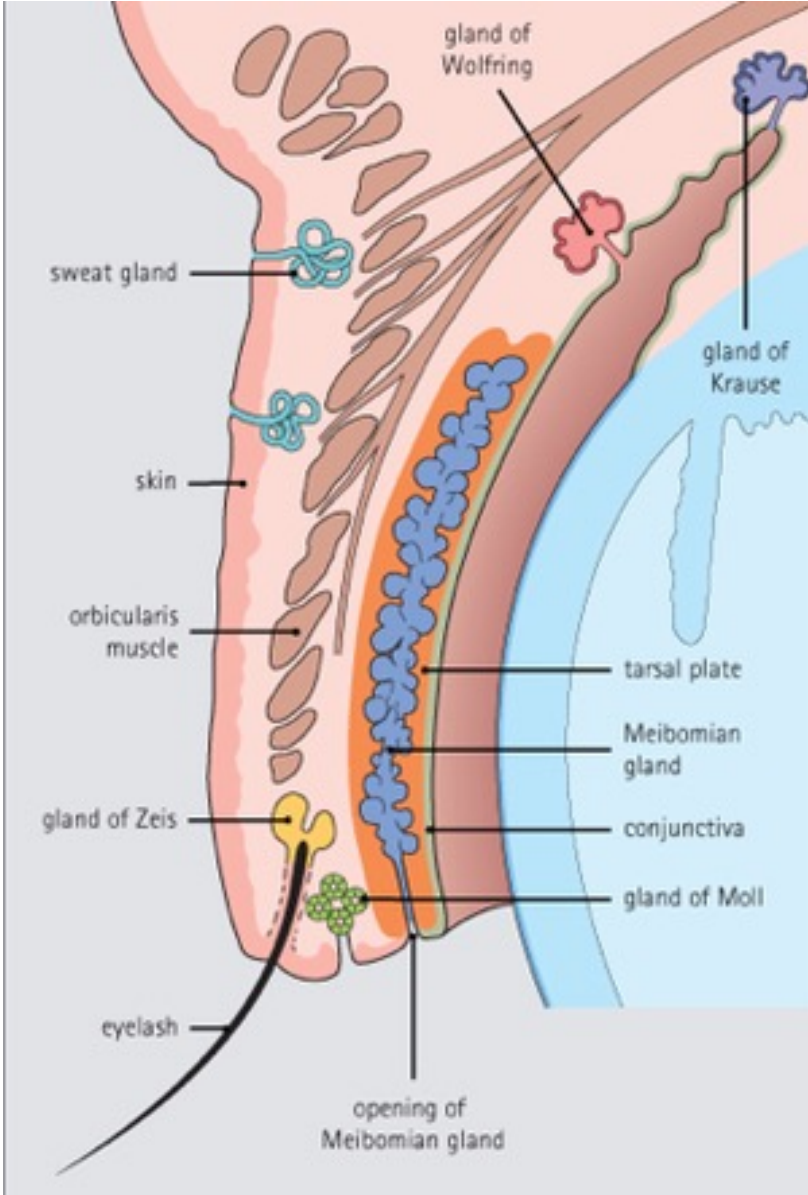
- Can be external (glands of Zeis & Moll) or internal (Meibomian gland): [Images](#)
- Acute onset, red, **painful** swelling, at lid margin
- Usually *staph* infection
- Tx: warm compresses 5-10 min QID, gentle massage, stop wearing eye makeup, consider gentle scrubbing at lash line with soft toothbrush and baby “no more tears” shampoo
- Most self-resolve in 1-2 weeks, may add erythromycin ophthalmic ointment

Chalazion

- Obstruction of Zeis or Meibomian gland: [Images](#)
- Slow growing (days to weeks), firm, **painless** swelling, less red than hordeolum, can be middle of eyelid, can be external or internal
- Lipogranuloma, not an infection
- Tx: warm compresses 5-10 min QID, consider gentle scrubbing at lash line with soft toothbrush and baby “no more tears” shampoo, antibiotics not indicated
- Most self-resolve but may take months
- Refer to ophthalmology for possible excision if persistent



Hordeolum



Chalazion

