

Socratic Room: **ABX2018**

Question

5 day old F – 37+2 week born by c-section to G2P1 afebrile mom with PROM – noted to have brief episodes of leftward eye deviation with concomitant desaturations. Mom had good prenatal care and her labs, including GBS, are all negative. Stat EEG, CBC, CMP, DsB, and HUS are currently pending.

T

36.8

HR

128

RR

39

BP

81/53

SpO₂

99% on CPAP 10

Exam

Normal appearing infant when you notice L-sided eye deviation during your exam.

Answer Choices

- A. Cefotaxime to cover GBS & E.coli (top two causes of neonatal bacterial meningitis) and Acyclovir to cover HSV given the exam findings
- B. Ampicillin for Listeria, Cefotaxime for GBS & E. coli, and Acyclovir for HSV given the exam findings
- C. Ampicillin and Gentamicin because this covers the most likely organisms in a child this age
- D. No antibiotics are recommended until an LP is done and the meningo-encephalitis panel results will be back within 1-2 hours
- E. Ampicillin for GBS (the most common etiology of neonatal meningitis) and Acyclovir for HSV given current presentation and findings



Bugs & Drugs Rapid Review

Answer: B

1000 WEST CARSON STREET TORRANCE, CA 90509
PHONE (310) 222-2333 FAX (310) 867-5309

MELODIE MIRANDA, M.D.

SHOM DASGUPTA-TSIKINAS, M.D.

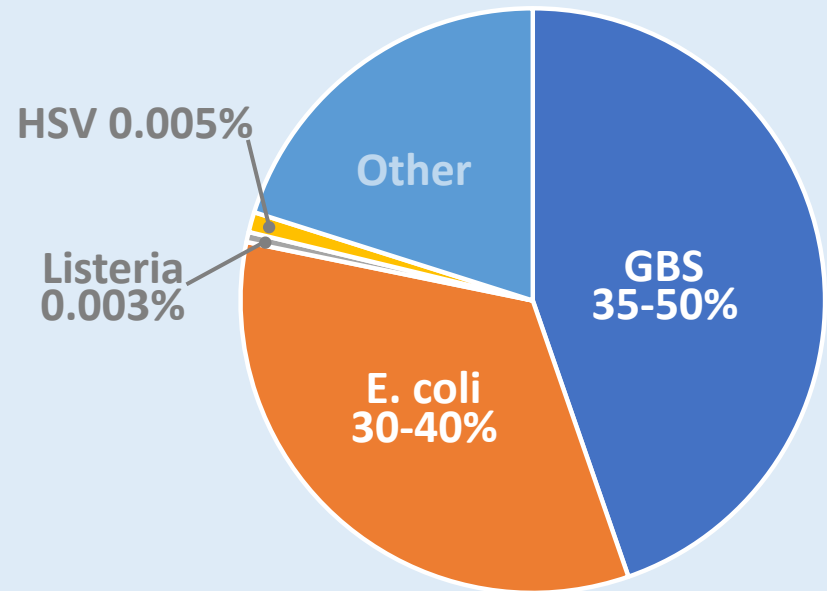
MICHAEL BOLARIS, M.D.

NAME Harbor-UCLA Pediatric Housestaff

DOB 11-01-2017

R_x Antibiotic Didactics - take one every week with food

Rates of neonatal Listeria and early-onset GBS have significantly dropped since the adoption of routine GBS screening and prophylaxis.



antibiotic czar

SIGNATURE

03-02-2018

DATE