Apophyseal Avulsion Fractures of the Hip and Pelvis

BART I. MCKINNEY, MD; CORY NELSON, MD; WESLEY CARRION, MD

educational objectives

As a result of reading this article, physicians should be able to:

1. Describe the anatomy and mechanism of injury associated with apophyseal avulsion fractures of the hip and pelvis.

2. List the different stages of nonoperative management in patients with apophyseal avulsion.

3. Discuss the operative treatment options and surgical approaches for treatment of these injuries.

4. Identify the controversies and common complications in the treatment of apophyseal avulsion fractures of the hip and pelvis.

Apophyseal avulsion fractures of the hip and pelvis are injuries that usually occur in the adolescent athlete. However they may present in a patient as late as the mid-20s.[1] If not properly diagnosed and treated, these injuries can be debilitating to an adolescent athlete. An increase of adolescent participation in competitive sporting activities and better musculoskeletal imaging techniques has led to an increased awareness of these injuries by the medical community. Apophyseal avulsion fractures are usually the result of a sudden forceful concentric or eccentric contraction of the muscle attached to the apophysis. Like other pediatric fractures, apophyseal avulsion fractures fail through the physis.[2] The primary age for these injuries to occur is between 14 and 25 years.[1,3,4]

This article reviews the most common sites of avulsions, anatomy, findings on history and physical examination, imaging commonly used in establishing the diagnosis, treatment, physical therapy protocol, and when these patients should return to sports. While the mainstay of treatment is nonoperative, controversies exist regarding operative treatment. What are the indications for surgery? If these injuries are to be treated operatively, what type of fixation should be used? This article will provide the reader with a better understanding of these controversies and what recommendations are in the literature.

COMMON SITES OF AVULSION IN THE HIP AND PELVIS

Metzmaker and Pappas[3] reviewed 27 cases of avulsion fractures and found the most common location to be the anterior superior iliac spine. Other common locations that were found included the ischial tuberosity, anterior inferior iliac spine, lesser trochanter and iliac crest.[3] In the largest study evaluating these injuries,

Drs McKinney, Nelson, and Carrion are from Stony Brook University Hospital, Stony Brook, New York.

Drs McKinney, Nelson, and Carrion have no relevant financial relationships to disclose. Dr Morgan, CME Editor, has disclosed the following relevant financial relationships: Stryker, speakers bureau; Smith & Nephew, speakers bureau, research grant recipient; AO International, speakers bureau, research grant recipient; Synthes, institutional support. Dr D'Ambrosia, Editor-in-Chief, has no relevant financial relationships to disclose. The staff of ORTHOPEDICS have no relevant financial relationships to disclose.

Correspondence should be addressed to Bart I. McKinney, MD, 3176 Birdseye Circle, Gulf Breeze, FL 32563.

cme ARTICLE

Cover Story

Cover illustration © Lisa Clark

Rossi and Dragoni[4] found the most common locations were the ischial tuberosity (54%), anterior inferior iliac spine (22%), anterior superior iliac spine (19%), superior corner of pubic symphysis (3%), and iliac crest (1%). Soccer (74 cases) and gymnastics (55 cases) had the highest number of avulsion fractures documented. We feel the difference in the two studies is most likely due to sample size. Metzmaker and Pappas[3] reviewed a case series of 27 patients, while Rossi and Dragoni[4] reviewed >1000 radiographs and found 203 avulsion fractures. Apophyseal avulsion fractures of the greater trochanter have also been documented in the literature.[5-8] Although rare, bilateral avulsion fractures can occur.[9]

Anatomy

In order to properly diagnosis and treat these injuries, it is vital to understand the anatomy associated with the apophyseal avulsion fracture (Figure 1). The direct head of the rectus femoris muscle originates from the anterior inferior iliac spine and inserts through the common quadriceps tendon onto the patella. Because it crosses two joints, patients with anterior inferior iliac spine avulsion fractures may have weakness in both hip flexion and knee extension. The anterior superior iliac spine is the origin of the sartorius and tensor fascia lata. Like an anterior inferior iliac spine avulsion, weakness of hip flexion and knee extension may be present in someone with an anterior superior iliac spine avulsion fracture. There may even be some loss of hip abduction in anterior superior iliac spine avulsion fractures as the sartorius is a weak hip abductor.

External and abdominal obliques originate from the iliac crest. Apophyseal avulsion fractures of the iliac crest are usually the result of a trunk twisting injury. The proximal attachment site of the hamstrings is the ischial tuberosity. Weakness of knee flexion and hip extension is a characteristic of ischial tuberosity avulsion fracture. The hip adductors originate from the pubic symphysis and insert onto the femur. An adolescent athlete with pubic symphysis avulsion fracture will have pain and weakness with hip adduction. The lesser trochanter can also be a site of apophyseal avulsion fracture. The iliopsoas muscle inserts onto the lesser trochanter and flexes the hip. The insertion of the hip abductors on the greater trochanter is another site for an apophyseal avulsion fracture.

In their classic article describing growth plate injuries, Salter and Harris[2] describe 2 types of epiphysis: a traction epiphysis and a pressure epiphysis. A traction epiphysis is the site of the insertion or origin of a major muscle or muscle group. A pressure epiphysis is situated at the end of a long bone and is subjected to pressure across the joint. They state that the weakest point of a traction epiphysis is the epiphyseal plate because the Sharpey's fibers attaching the muscle to the epiphysis are stronger than the junction of cells between the calcified and uncalcified epiphysis.[2] Salter and Harris[2] found this weak junction of cells where the separation usually occurs in the zone of hypertrophy.

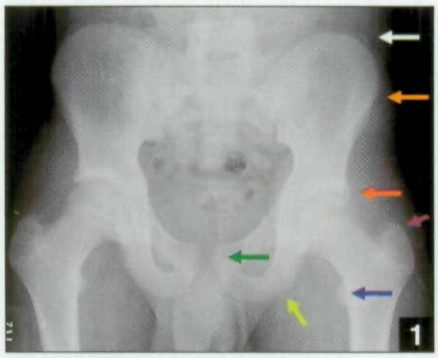

Figure 1: Radiograph demonstrating the possible sites of apophyseal avulsion fractures about the hip and pelvis. Iliac crest (white arrow), ASIS (orange arrow), AIIS (red arrow), pubic symphysis (green arrow), ischial tuberosity (yellow arrow), greater trochanter (purple arrow), lesser trochanter (blue arrow). **Figure 2:** Radiograph of a 15-year-old boy, who sustained an injury while playing hockey, demonstrates an avulsion fracture of the anterior inferior iliac spine (arrow).

History and Physical Examination

These patients usually present with a history of sudden pain during an activity such as a sporting event. The pain is most severe during activity and improves with rest. Swelling and local tenderness may be appreciated by palpation. The patient may actively guard against contraction of the musculature attached to the injured apophysis. Passive stretch of these muscles will reproduce the pain. A limp may be present. There is a noticeable weakness in the muscle group attached to the avulsed apophysis compared to the contralateral side.

The examination of these patients may mimic an acute episode of apophysitis. It is important to know the signs of apophysitis and how it can be differentiated from an acute avulsion fracture. Apophysitis is an inflammation of the apophysis that is usually caused by overuse or repetitive traction to the physis. Both patients with apophysitis and avulsions fractures may have tenderness and swelling at the site of injury. However patients with apophysitis usually do not have significant bruising or ecchymosis, which may be present with an acute fracture. Patients with an apophyseal avulsion fracture should be able to recall a specific event that triggered the pain compared to apophysitis, which has a more insidious onset of pain.

Imaging

A plain anteroposterior (AP) radiograph of the pelvis may demonstrate an avulsed fragment (Figure 2). If the fracture is not evident on the AP radiograph, additional oblique or axial projections may help delineate the fracture. However, these injuries are frequently missed

on initial radiographs. A computed tomography (CT) scan is excellent for detailing bony anatomy and demonstrating any displaced fracture fragments (Figure 3). Magnetic resonance imaging may be useful in evaluating apophysitis and avulsions in children who ossification center has yet to ossify (Figure 4). Recently, ultrasound has been used to diagnose these injuries. In the hands of a skilled technologist, ultrasound has been shown to be both cost effective and accurate in diagnosing apophyseal avulsion fractures.[10]

CLASSIFICATION

No definitive classification system exists for all apophyseal avulsion fractures of the hip and pelvis. Classification of these injuries is usually based on the location and amount of displacement. Torode and Zieg[11] classified all pediatric pelvis fractures. Type I are avulsion fractures. Type II fractures are iliac wing fractures. Type III fractures include simple ring fractures. And type IV fractures are ring disruption fractures. Martin and Pipkin[12] in 1957 classified ischial tuberosity avulsion fractures into 3 groups: nondisplaced fractures, acute avulsion fractures, and old nonunited fractures.

We propose a modification to Martin and Pipkin's classification to help guide treatment options (Table 1). The Martin and Pipkin classification was based on a specific site of injury, the ischial tuberosity, and does not account for the amount of displacement. A classification system that accounts for displacement will aid the physician in selecting the appropriate treatment (Figure 5).

NONOPERATIVE TREATMENT

Nonoperative treatment has shown to be successful in many of these injuries. Metzmaker and Pappas[3] demonstrated successful nonoperative treatment of 27 avulsion fractures using a 5-phase protocol (Table 2).

Stage I consists of rest, cryotherapy, and the use of analgesics for the first week after the initial injury. Seven days after the initial injury, the patient begins stage II, which consists of gentle active and passive motion. Once 75% of motion is regained, the patient may progress to resistance exercises. Stage III consists of guided resistance exercises and typically begins two to three weeks after initial injury. Stage IV, approximately 1 to 2 months after initial injury, focuses on stretching and strengthening with an emphasis on sports-specific exercises. Stage V is a return to competitive sports and should be started no earlier than 2 months after the initial injury.

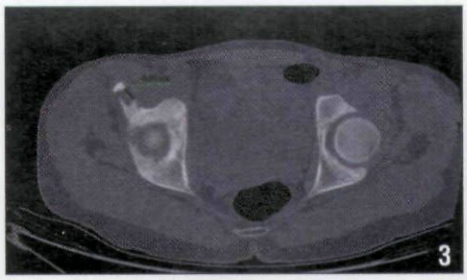

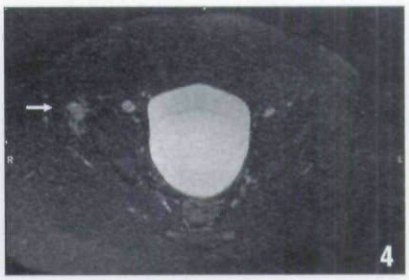

Figure 3: CT scan of the patient in Figure 2 demonstrates 8 mm of displacement. Conservative treatment was successful in this patient. **Figure 4:** MRI of a 13-year-old boy, who reported hip pain after kicking a ball, demonstrates increased signal around the anterior superior iliac spine suggesting an apophyseal avulsion fracture (arrow). Conservative treatment was indicated in this minimally displaced fracture.

Table 1

Classification of Apophyseal Avulsion Fractures

Type I	Nondisplaced fractures
Type II	Displacement up to 2 cm
Type III	Displacement >2 cm
Type IV	Symptomatic nonunions or painful exostosis

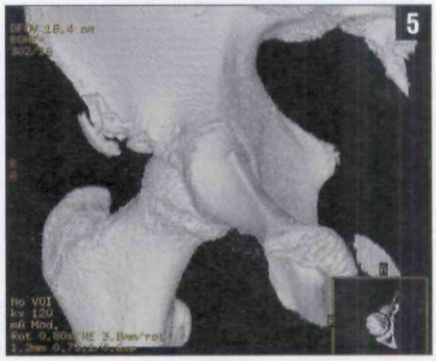

Figure 5: 3D reconstructive CT scan of a 14-year-old boy, who reported groin pain while playing sports, demonstrates a displaced anterior inferior iliac spine avulsion fracture. Conservative treatment was successful in this patient.

SURGICAL INDICATIONS

Most authors agree that nonoperative management with a guided rehabilitation program should be the initial option for pelvic avulsion fractures. However, surgical intervention has been indicated in certain instances. Sundar and Carty[13] followed 22 patients with avulsion fractures over 44 months. They found a limitation of sporting ability in 10 of the 22 patients with persistent symptoms in 6 patients, mostly in those with ischial avulsion injuries.[13] Many authors describe displacement of 2 to 3 cm as an indication for surgery.[5,14-24] Painful nonunion, inability to return to competitive sports and exostosis formation are other indications for surgical intervention.[12,14,15,19,22] Other authors feel that any displaced greater trochanter avulsion fractures should be treated operatively due to the significant role of the abductor musculature in both hip mechanics and gait causing functional disability.[5,7]

The notion that open reduction and internal fixation (ORIF) should be considered for fractures that are displaced >2 cm was reported in a series of 5 pelvic avulsions and 1 case of bilateral tibial tubercle avulsions.[23] Only 2 of the 5 cases presented were treated operatively. The authors' recommendation for ORIF of fragments displaced >2 cm was only for ischial avulsions.

Significantly displaced avulsion fragments raise 2 major concerns when considering nonoperative treatment. The first is whether the fragment will develop into a

Table 2

Physical Therapy Protocol[2]

Phase	Postinjury (d)	Subjective Pain	Palpation Tenderness	ROM	Muscle Strength	Activity Level	Radiographic Appearance
I	0-7	Moderate	Moderate-severe	Very limited	Poor	None, protected WB	Osseous separation
II	7 to 14-20	Minimal	Moderate	Improving with guided exercise	Fair	Protected WB, guided exercise	Osseous separation
III	14-20 to 30	Minimal with stress	Moderate	Improving with gentle stress	Good	Guided exercise, resistance	Early callus
IV	30-60	None	Minimal	Normal	Good-normal	Limited athletic participation	Maturing callus
V	60 to return	None	None	Normal	Normal	Full activity	Maturing callus

Abbreviation: ROM, range of motion; WB, weight bearing.

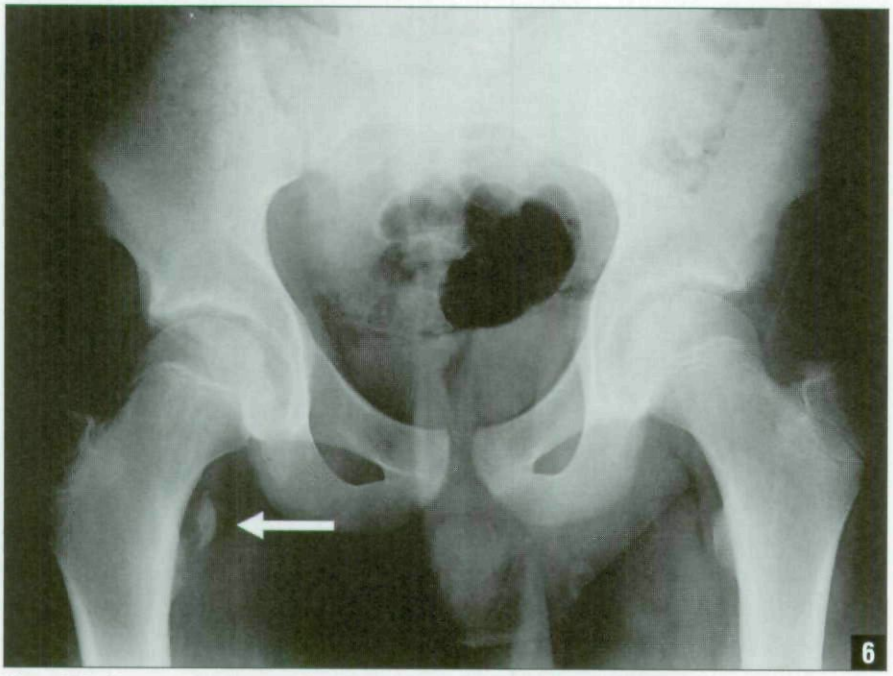

Figure 6: Radiograph of a 13-year-old boy with an avulsion of the lesser trochanter (arrow). Conservative treatment is indicated in these avulsion fractures unless painful nonunion or symptomatic exostosis develops.

nonunion because of the displacement. The second major concern is the loss of strength that may occur from muscle shortening. Others argue that clinical experience with patients who have had >5 cm of shortening in muscle length for other reasons have eventually regained muscle strength equivalent to the contralateral side.[3] Throughout the literature mainly isolated cases have been published in which a surgical decision was made. Other authors have used the 2- to 3-cm displacement criteria described for ischial tuberosity avulsion fractures as an indication for surgical intervention of displaced anterior superior iliac spine and anterior inferior iliac spine avulsions fractures.[15,17,19,20]

It is unclear in the literature whether surgical intervention allows a patient to return to high level sports sooner. Veselko and Smrkolj[19] reported on 2 adolescent athletes that underwent ORIF of the anterior superior iliac spine. These 2 patients were able to return to play at 3 and 4 weeks from the date of injury. Open reduction and internal fixation may be advocated in certain high end professional or collegiate athletes for a shorter convalescence. However more studies are needed to determine if high level athletes truly return to sports faster with operative intervention.

Operative Treatment

Lesser Trochanter, Iliac Crest, and Pubic Symphysis

A review of the English-language literature revealed no case reports documenting operative treatment of acute apophyseal avulsion fracture of the lesser trochanter, iliac crest or pubic symphysis in the adolescent (Figure 6). Nonoperative treatment is recommended for these injuries except Type IV fractures (symptomatic nonunion or painful exostosis). Small symptomatic nonunions and painful exostosis should be excised and the muscle reattached. Large avulsion nonunions, >2 cm, should have nonunion repair attempted with internal fixation. The choice of internal fixation would be dependent on the shape and location of the fragment.

Ischial Tuberosity

Recently a case report for ORIF of an ischial tuberosity avulsion sustained in a jumping adolescent athlete was de-

scribed.[24] The fracture was displaced 2.5 cm. The authors used a prone position and a surgical approach through the gluteal crease and identified the plane between the inferior border of the gluteus maximus and the hamstrings. The fracture fragment was identified at the proximal hamstring tendons and reduced with hip extension and knee flexion. The fragment was stabilized with 2 cancellous screws (4 and 6.5 mm) and washers. At 4 months postoperatively, the patient had resumed all normal activity including playing rugby football. At final follow-up, the patient was asymptomatic and radiographs showed complete healing of the fracture.

Greater Trochanter

Several case reports have been published documenting greater trochanter avulsion fractures treated with surgical fixation.[5-7] Mbubaegbu[5] reported the case of a 14-year-old boy with a displaced greater trochanter avulsion fracture who underwent open reduction and internal fixation. This fracture was fixed using a single half-threaded cancellous screw. The patient progressed to full weight bearing at 4 weeks and recovery was uneventful. O'Rourke and Weinstein[6] describe a 13-year-old boy who underwent closed reduction and percutaneous cannulated screw fixation for a displaced avulsion fracture of the greater trochanter. At 8 months postoperatively, the patient developed worsening pain with running. The patient was found to have osteonecrosis of the entire femoral head with collapse. Five years postoperatively, the patient had mild-moderate pain, 20° flexion contracture, limb-length discrepancy of 1.5 cm and did not participate in organized athletic activities. Woods et al[7] describe a case report in which they use a direct lateral approach to the greater trochanter splitting the gluteus maximus. For fixation, they used two 6.5-mm partial threaded cancellous screws with washers. According to their case report, the patient went on to an uneventful recovery.

Anterior Superior Iliac Spine

The anterior superior iliac spine can be approached using a direct incision over the anterior aspect of the iliac crest. Depending on the fragment size 1 or 2 screws with or with washers may be used. Use of a tension band technique has also been described in the treatment these fractures.[17] In a case series of 6 patients, Kosanovic et al[17] describe a techniques of fixation using 2 Kirschner wires and a wire loop for internal fixation. All 6 patients were able to return to sports in 6 weeks.

Anterior Inferior Iliac Spine

One case report in the literature describes the operative treatment of an anterior inferior iliac spine avulsion fracture with a modified Smith-Peterson approach.[15] These authors used a 6.5 screw with washer for fixation as well. One year postoperatively, he was pain free, with full leg strength and able to participate actively in sport.

Postoperative Protocol

Most authors recommend an initial period of nonweight bearing (7-10 days) followed by a period of progressive weight bearing (3-6 weeks), and physical therapy. Some authors allow return to sports at 4 to 6 weeks[18,19] while other authors recommend return at 3 to 4 months[24] postoperatively.

Complications

Most apophyseal avulsion fractures heal with excellent results. However there have been a few documented complications. The 2 most commonly reported complications include painful nonunion and exostosis formaton.[13,22] Occasionally fragmentation, lysis, or exostosis may occur that can mimic many neoplastic and infectious conditions.[13] If a painful nonunion develops, it is generally recommended to treat these with operative fixation. A symptomatic exostosis may require excision for resolution of symptoms. The most severe complication that may arise is osteonecrosis of the femoral epiphysis after avulsion of the greater trochanter. Osteonecrosis has been reported in greater trochanter avulsion fractures treated both operative and nonoperatively.[6] Displaced ischial spine fractures have also been found to cause sciatic nerve irritation mimicking neurological pathology.[25-27]

Table 3

Indications for Operative Intervention

All Type IV alvusion fractures
Type III greater trochanter avulsion fractures
Type II & III ischial tuberosity avulsion fractures causing neurologic symptoms

Table 4

Relative Indications for Operative Intervention

Type II greater trochanter avulsion fractures
Type III ASIS, AIIS, and ischial tuberosity avulsion fractures that have failed conservative treatment
Type III avulsion fractures in professional or collegiate athletes

Abbreviations: AIIS, anterior inferior iliac spine; ASIS, anterior superior iliac spine.

CONCLUSION

Apophyseal avulsion fractures of the hip and pelvis are infrequent pediatric fractures. However with increasingly active children and adolescents in today's population and better imaging techniques, these fractures are becoming increasingly more recognized. These fractures can be easily missed. When these fractures are diagnosed and treated appropriately, nonsurgical management is usually successful. A 5-stage rehabilitation protocol has been proposed in the literature and should be the initial management for the majority of these injuries. Multiple case reports and case series document excellent results with a guided nonoperative treatment protocol.

Based on our experience and review of the literature, we recommend the following indications for treatment of apophyseal avulsion fractures of the hip and pelvis (Tables 3, 4).

Surgical treatment should be used for painful nonunions and symptomatic exostosis (Type IV avulsion fractures). Any displaced ischial tuberosity avulsion fracture causing neurological symptoms should be either excised with reattachment of the hamstring musculature (small avulsed fragments) or undergo open reduction and internal fixation (large fragments). Significantly displaced greater trochanter avulsion fractures (Type III) should be reduced and internal fixation applied. This is necessary to maintain proper tension on the hip abductor complex and to prevent a child or adolescent from developing a trendelenburg gait.

A few relative indications exist for operative treatment of apophyseal avulsions fractures. Greater trochanter avulsion fractures displaced <2 cm (Type II) may benefit from surgical fixation lessening the chance of sequential displacement and development of trendelenburg gait due to abductor muscle shortening. This area is controversial and further study is needed in the treatment of these rare injuries. Good results have been reported in the literature with operative treatment of significantly displaced (Type III) anterior superior iliac spine, anterior inferior iliac spine and ischial tuberosity avulsion fractures. If a patient with 1 of these fractures who has failed an initial period of conservative treatment or is a professional/collegiate high-end athlete, then surgical intervention may be warranted.

Common complications of apophyseal avulsion fractures include painful nonunion and exostosis. Regardless of treatment, osteonecrosis may develop in a patient with an apophyseal avulsion of the greater trochanter. The treating physician must counsel the patient and parents on this possible complication. Numerous case reports have documented neurological symptoms with displaced ischial tuberosity fractures. If this occurs, surgical treatment should be implemented.

With careful understanding of the anatomy, mechanism of injury and treatment options, these fractures can be successfully diagnosed and treated.

References

1. Fernbach SK, Wilkinson RH: Avulsion injuries of the pelvis and proximal femur. *AJR Am J Roentgenol.* 1981; 137(3):581-584.
2. Salter RB, Harris WR. Injuries involving the epiphyseal plate. *J Bone Joint Surg Am.* 1963; 45:587-622.
3. Metzmaker JN, Pappas AM. Avulsion fractures of the pelvis. *Am J Sports Med.* 1985; 13(5):349-358.
4. Rossi F, Dragoni S. Acute avulsion fractures of the pelvis in adolescent competitive athletes: prevalence, location and sports distribution of 203 cases collected. *Skeletal Radiol.* 2001; 30(3):127-131.
5. Mbubaegbu CE, O'Doherty D, Shenolikar A. Traumatic apophyseal avulsion of the greater trochanter: case report and review of the literature. *Injury.* 1998; 29(8):647-649.
6. O'Rourke MR, Weinstein SL. Osteonecrosis following isolated avulsion fracture of the greater trochanter in children: a report of two cases. *J Bone Joint Surg Am.* 2003; 85(10):2000-2005.
7. Wood JJ, Rajput R, Ward AJ. Avulsion fracture of the greater trochanter of the femur: recommendations for closed reduction of the apophyseal injury. *Injury Extra.* 2005; 36:255-258.
8. Bloome DM, Thompson JD. Apophyseal fracture of the greater trochanter. *South Med J.* 2000; 93(8):832-833.
9. Khoury MB, Kirks DR, Martinez S, Apple J. Bilateral avulsion fractures of the anterior superior iliac spines in sprinters. *Skeletal Radiol.* 1985; 13(1):65-67.
10. Pisacano RM, Miller TT. Comparing sonography with MR imaging of apophyseal injuries of the pelvis in four boys. *AJR Am J Roentgenol.* 2003; 181(1):223-230.
11. Torode I, Zieg D. Pelvic fractures in children. *J Pediatr Orthop.* 1985; 5(1):76-84.
12. Martin TA, Pipkin G. Treatment of avulsion of the ischial tuberosity. *Clin Orthop Relat Res.* 1957; (10):108-18.
13. Sundar M, Carty H. Avulsion fractures of the pelvis in children: a report of 32 fractures and their outcome. *Skeletal Radiol.* 1994; 23(2):85-90.
14. Wooten JR, Cross MJ, Holt KWG. Avulsion of the ischial apophysis: The case for open reduction and internal fixation. *J Bone Joint Surg Br.* 1990; 72(4):625.
15. Rajasekhar C, Kumar KS, Bhamra MS. Avulsion fractures of the anterior inferior iliac spine: the case for surgical intervention. *Int Orthop.* 2001; 24(6):364-365.
16. Saluan PM, Weiker GG: Avulsion of the anterior inferior iliac spine. *Orthopedics.* 1997; 20(6):558-559.
17. Kosanovic M, Brikej D, Komadina R, Buhanec B, Pilih IA, Vlaovi M. Operative treatment of avulsion fractures of the anterior superior iliac spine according to the tension band principle. *Arch Orthop Trauma Surg.* 2002; 122(8):421-423.
18. Pointinger H, Munk P, Poeschl GP. Avulsion fracture of the anterior superior iliac spine following apophysitis. *Br J Sports Med.* 2003; 37(4):361-362.
19. Veselko M, Smrkolj V. Avulsion of the anterior-superior iliac spine athletes: case reports. *J Trauma.* 1994; 36(3):444-446.
20. Meyer NJ, Schuab JP, Orton D. Traumatic unilateral avulsion of the anterior superior and inferior iliac spines with anterior dislocation of the hip: a case report. *J Orthop Trauma.* 2001; 15(2):137-140.
21. White KK, Williams SK, Mubarak SJ. Definition of two types of anterior superior iliac spine avulsion fractures. *J Pediatr Orthop.* 2002; 22(5):578-582.
22. Resnick JM, Carrasco CH, Edeiken J, Yasko AW, Ro JY, Ayala AG. Avulsion fracture of the anterior inferior iliac spine with abundant reactive ossification in the soft tissue. *Skeletal Radiol.* 1996; 25(6):580-584.
23. Howard FM, Piha RJ: Fractures of the apophyses in adolescent athletes. *JAMA.* 1965; (192):842-844.
24. Kaneyama S, Yoshida K, Matsushima S, Wakami T, Tsunoda M, Doita M. A surgical approach for an avulsion fracture of the ischial tuberosity. A case report. *J Orthop Trauma.* 2006; 20(5):363-365.
25. Miller A, Stedman GH, Beisaw NE, et al.: Sciatica caused by an avulsion fracture of the ischial tuberosity. *J Bone Joint Surg Am.* 1987; 69(1):143-145.
26. Spinner RJ, Atkinson JL, Wenger DE, Stuart MJ. Tardy sciatic nerve palsy following apophyseal avulsion fracture of the ischial tuberosity: case report. *J Neurosurg.* 1998; 89(5):819-821.
27. Dosani A, Giannoudis PV, Waseem M, Hinsche A, Smith RM. Unusual presentation of sciatica in a 14-year-old girl. *Injury.* 2004; 35(10):1071-1072.